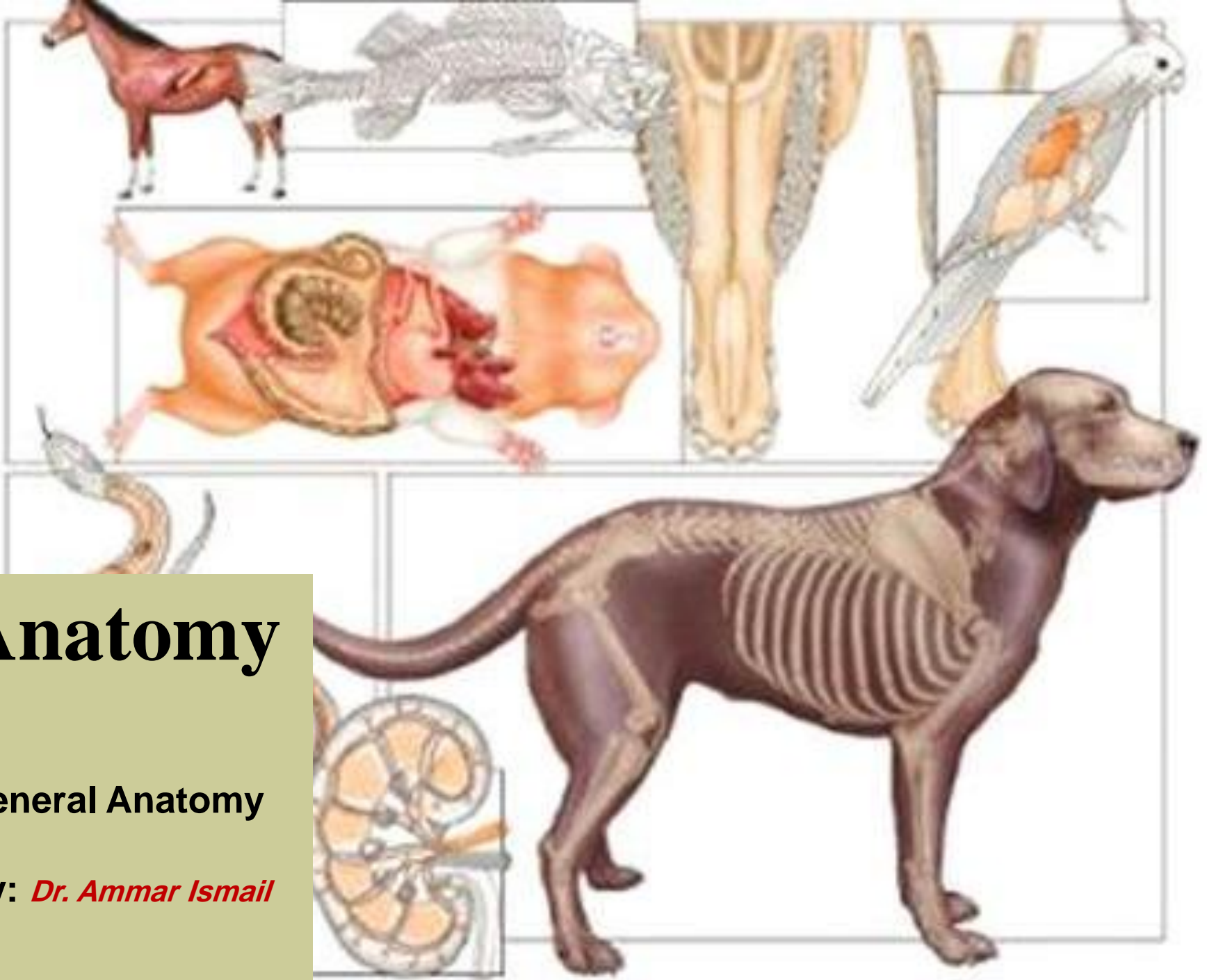


Anatomy

General Anatomy

By: *Dr. Ammar Ismail*



Introduction:

- Anatomy:(Greek word)
- Ana ----- a part
- Tomy ----- cut

Anatomy: is the study of the structures of a body and relation of its parts. The subject is usually studied by dissection and observation.

It is one of the oldest branches of biological science dating back at least to the 4th century B.C. when the Greek philosopher Aristotle published some of his observation on structures of fish and animals for his work.

The study of anatomy involves three basic facts of information:{ name, location or position and function of anatomic structures}. Its include :

- 1-Special anatomy
- 2- Comparative anatomy.
- 3- Surgical anatomy.

Special anatomy: study species of animals like (horse, cow,..... etc.)

Comparative anatomy: describe and compare the anatomical structures in different species.

Surgical anatomy(applied anatomy): study anatomical facts of body organs related with surgical science.

Types of anatomy

- Anatomical science divided according to the type of study into:
- 1- Gross or macroscopic anatomy (in situ)
- 2- Microscopic anatomy or (Histology).
- 3- Developmental anatomy (Embryology).
- 4- Neuroanatomy.

Gross or macroscopic anatomy

- **Special Anatomy:** Study of biological structure of a particular species of animal.
- **Comparative anatomy:** Description and comparison of anatomy of different species of animals.
- **Systemic anatomy:** Study of different systems in animal body one after the other. e.g. skeletal system, muscular system, angiology, neurologyetc.
- **Regional anatomy:** Study the anatomy of all the structures present in a particular region of body. e.g. bones, muscles, blood vessels, lymphatics and nerves of forelimb.



Terminology Used In Anatomy

- Anatomical terms must have the same meaning regardless of the orientation of the animal or the position of the observer

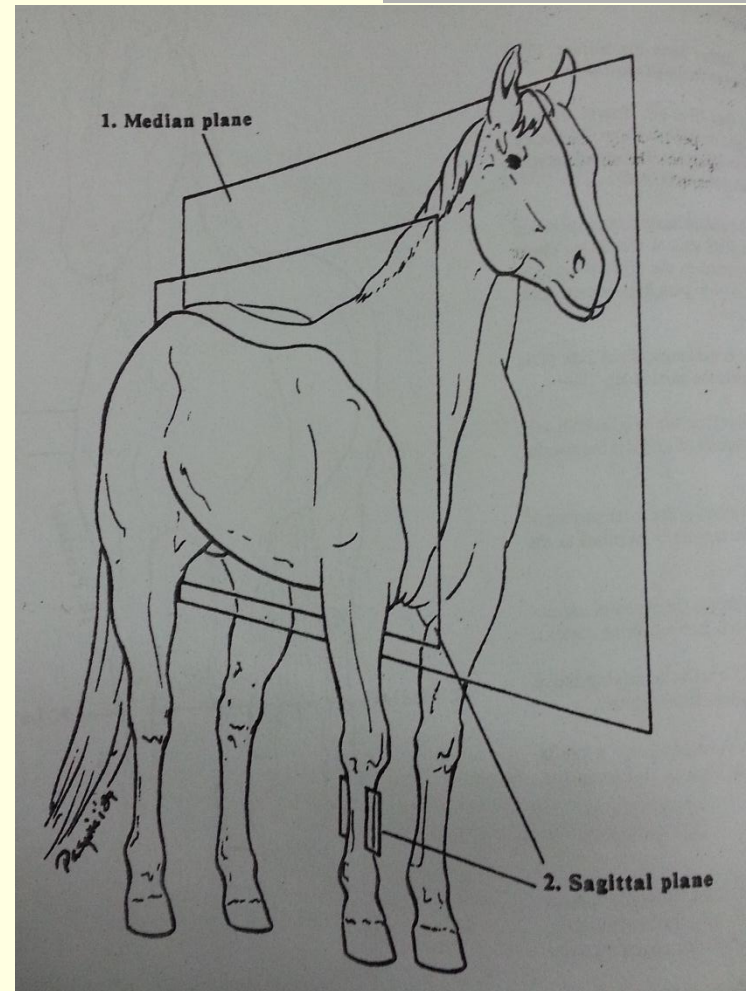
Systemic anatomy: include

- **Osteology:** describe the bones and cartilages which are formed the body skeleton.
- **Arthrology-Syndesmology:** Study of joints or articulations and its ligaments .
- **Myology:** Study the Muscles and their tendons.
- **Splanchnology:** describe the viscera (like digestive , respiratory, urogenital systems) also the endocrine glands and peritoneum .
- **Angiology:** describe the heart, blood vessels (arteries and veins), lymphatic vessels.
- **Neurology:** Study of nervous system.
- **Aesthesiology:** Study of skin and sense organs.

Anatomical Planes

(imaginary slice through animal body)

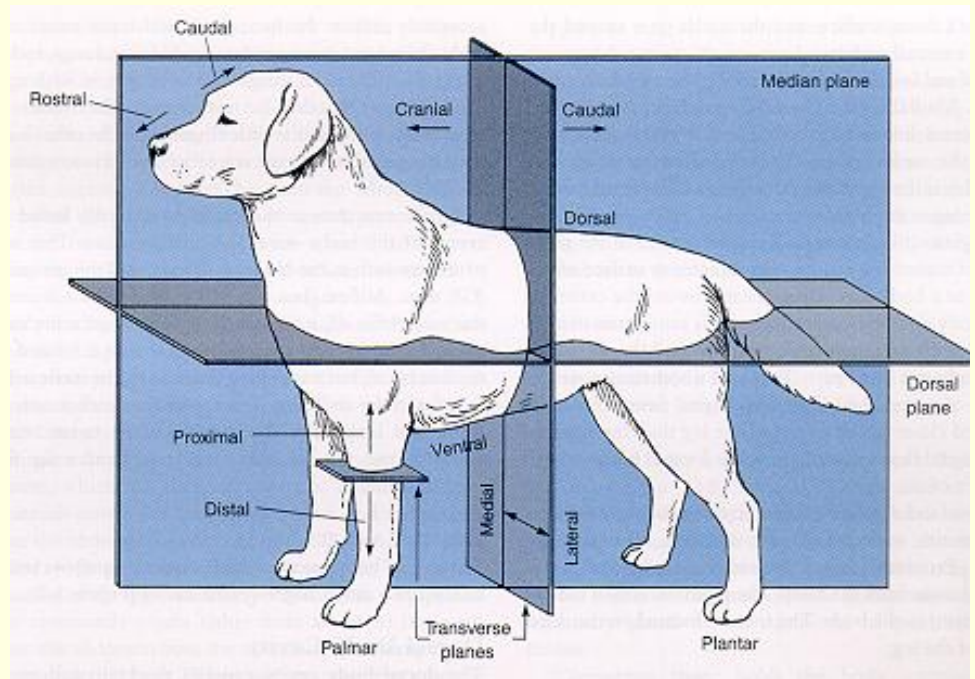
- **Median plane:** Dividing the body into equal right and left portions.
- **Sagittal(para median) plane:** a plane dividing the body into unequal right and left portions it is parallel to the median plane.



Anatomical Planes

Frontal plane: a plane perpendicular to both median and transverse planes, dividing body into dorsal and ventral portions.

Transverse plane: a plane perpendicular to the median plane, dividing the body into cranial and caudal parts. A transverse plane also crosses an organ or limb at a right angle to its long axis



Topographical = Descriptive terms

Dorsal : away from the ground. Also the surface below the proximal end the carpus and tarsus (the vertebrae are dorsal to the heart)

Ventral :toward to the ground (the tongue is ventral to the nasal cavity)

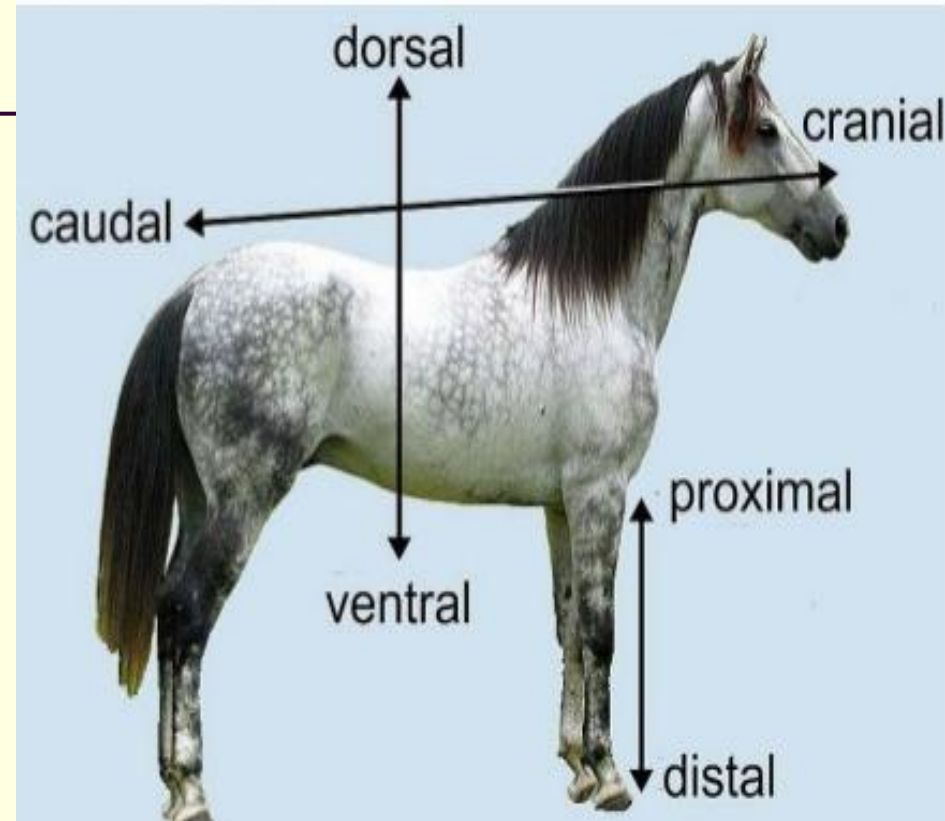
Cranial: toward the head (the head is cranial to the tail)

Caudal: toward the tail (the hind limb is caudal to the forelimb).

Rostral : a part on the head closer to the nose(the nose is rostral to the ears).

Proximal: nearest to the trunk or point of origin of a limb, vessel, nerve or organ(The elbow is proximal to the digit).

Distal: farther from the trunk or point of origin of a limb.



Topographical = Descriptive terms

- **Palmar:** the surface below the proximal end of the carpus directed caudally or toward the ground, thus replacing caudal for this part of the limb.(The dew claw of ox is on the palmar surface of the forelimb). The opposite, cranially facing side is the dorsal side.
- **Plantar:** the surface below the proximal end of the tarsus directed caudally or toward the ground. As in the forelimb, the opposite side is the dorsal side.
- **Medial:** toward the median plane (the chest is medial to the thoracic limbs).
- **Lateral :** farther from the median plane(The shoulder is lateral to the ribs).
- **Axial :** Towards the central line of body or any body part.
- **Abaxial :** Away from the central line of body or any body part.
- **Superior :** Above.
- **Inferior :** Below.
- **Superficial :** Close to surface.
- **Deep :** Beneath surface.

Topographical

